

Evaluation of a volunteered herbal recipe employed for the treatment of Uterine leiomyoma (Fibroid) in South-West Nigeria

Bamigboye J Taiwo^{1*}, Oluwole I Adeyemi², Samson O A Odukoya³, Olukemi T. Bamigboye-Taiwo^{4,5},
Faith O Obagunle¹, Tanwa Animasahun².

¹Department of Pharmaceutical Chemistry, Faculty of Pharmacy, Obafemi Awolowo University, Ile Ife, Nigeria

²Department of Pharmacology, Faculty of Pharmacy, Obafemi Awolowo University, Ile Ife, Nigeria.

³Department of Anatomy and Cell Biology, Faculty Basic Medical Sciences, Obafemi Awolowo University, Ile Ife, Nigeria.

⁴Department of Physiological Sciences, Faculty Basic Medical Sciences, Obafemi Awolowo University, Ile Ife, Nigeria.

⁵Department of Paediatric and Child Health, Faculty Clinical Sciences, Obafemi Awolowo University, Ile Ife, Nigeria.

ARTICLE INFO

Article history:

Received 15th July 2024

Revised 16th September 2024

Accepted 20th September 2024

Online

Published

Keywords:

Uterine leiomyoma,

medicinal herbs,

ethnomedicine,

fibrosis,

gynaecological tumors,

therapeutic intervention.

*Corresponding Author:

Bamigboye Josiah TAIWO
Email: bamit@oauife.edu.ng
Tel: +2348066507213

ABSTRACT

Background: Uterine fibroids, locally known as 'oyun iju' (false pregnancy in Yoruba dialect) are the most prevalent gynecologic tumors affecting 20 to 40 % of women of childbearing age. It is associated with high morbidity rates, high risk of adverse obstetric outcomes and a reduction in a woman's quality of life. However, there are few treatment options that are effective and which preserve the integrity of the uterus and fertility in affected women.

Aim of the study: This study investigated the safety and efficacy of a volunteered herbal recipe, 'CKNS' containing four Nigerian medicinal plants, used to manage uterine fibroid locally.

Materials and Methods: The crude extract of the recipe was prepared and its toxicity assessment was carried out using the method described by Lorke. Fibrosis was induced in rats with intramuscular administration of 200 µg of estradiol benzoate for 8 weeks. The rats were treated every 48 hours with different doses of extract, fermented corn water, or goserelin for 2 weeks, after which they were sacrificed following anesthesia with diethyl ether. Cardiac puncture was carried out to collect blood into sample tubes. Hematological and biochemical evaluations were carried out on the samples. Histological examination of the cross sections of the uteri of the studied animal was carried out. Data were analyzed using Graphpad Prism version 5.0 for Windows (Graphpad software, San Diego, California, USA).

Results: The acute toxicity test showed no death of animal occurred up to 5000 mg/Kg body weight dose. Histological examination confirmed induction of fibroid. Hematological and biochemical values of the studied animals were within normal range for rats, while the cross section of the uteri of the treatment group that received 1000 mg/kg body weight of the extract had normal mucosa, muscularis and adventitia, compared with the control group.

Conclusion: The recipe was found to be safe and to effectively reverse the induced fibrosis in rat uterus.

Introduction

Uterine fibroid (leiomyomas) is the most prevalent gynecologic non-cancerous tumors affecting 20-40 % of women of child bearing age globally^{1,2,3,4}. The aetiology of the disease is still unknown, but they are oestrogen- and progesterone-dependent tumors, as they rarely occur before menarche, while they are common during reproductive life, they mostly regress in size after menopause⁵. Fibroid disease showed wide health disparities, as it occurs more in black women than in the Caucasians^{5,6,7,8,9}. The incidence rate of fibroids in Nigeria had been reported to range from 17.9- 26 % as against 11 % in developed countries^{10,11,12,13}. It accounts for 3.2 – 7.8% of new gynaecological cases and 68.1% of hysterectomy cases in Nigeria¹⁴. The symptoms of uterine leiomyomas include heavy bleeding, pains and pressure on adjoining organs, leading to difficulty with bowel and bladder function and, in some cases, infertility and pregnancy complications or loss as well as a high risk of adverse obstetric outcomes^{15,16,17}. Uterine fibroid is a major public health challenge. The only treatment options for fibroid is hysterectomy while uterine arteries embolization, myolysis, myomectomy are surgical procedures to manage the disease. The side effects of the surgical options include complication arising from post-surgical excision of the fibroid, infertility, uterine scarring, infection to mother and fetus. Selective progesterone receptors modulator *e.g* mifepristone, asoprisnil and ulipristal acetate, developed for emergency contraception had been approved by the Federal Drug Administration in the United States for use in managing fibroid⁴. Other medications include the gonadotropin releasing hormone antagonist *e.g* elagolix, cetrorelix, antagon, oriahn, ganirelix and orgalutran. However, the use of progesterone receptor modulators leads to hot flashes, depression, decreased libido, insomnia, joint pain, androgenization and bone loss in the affected women. Also, after the cessation of therapy, regrowth of tumours occurs when normal hormonal fluctuations involved in menstrual cycle are reestablished^{18,19}. Recently, safety concerns have been raised for some drugs already available or under investigation for uterine fibroid²⁰. Therefore, there is a need for ongoing search to find efficient, cost effective, and safe anti-uterine fibroid drugs^{21,22}. Medicinal herbs have served as alternative in many traditional African communities for the local treatment of uterine fibroid for many years, but are largely uninvestigated. The aim of this study is to evaluate a volunteered herbal recipe from one of the experienced traditional medical practitioner in South-West Nigeria.

Materials and Methods

Medicinal herbs and fruit

The stem bark of *Kigelia africana* (Lam.) Benth (Bignonoaceae) was collected from Igbolaja, Lanlate, Ibarapa Local Government of Oyo State. The fruit of *Citrullus colocynthis* (L.) Schrad. (Cucurbitaceae) and the leaves of *Newbouldia laevis* (P. Beauv.) Seem. (Bignoniaceae) were collected from Eruwa while the leaves of *Spondias mombin* Linn. (Anacardaceae) were collected from Maya, both Towns in Oyo state, South West Nigeria. *K. africana*, *N. laevis* and *S. mombin* were identified and authenticated by Mr I.I. Ogunlowo, Department of Pharmacognosy, Faculty of Pharmacy Obafemi Awolowo University and were given a voucher number FPI 2096, FPI 2097, FPI 2098 for *K. Africana*, *S. mombin* and *N. laevis* respectively, while *C. colocynthis* was identified and authenticated at National Horticultural Research Institute, Idi-Ishin, Ibadan by comparison with herbarium specimen.

Animals

Ethical clearance No. IPH/OAU/12/2352 was obtained from the Health Research Ethics Committee (HREC), Obafemi Awolowo University, Ile-Ife. All the animals used were bred in the Multidisciplinary Departmental Laboratory Animal House, Obafemi Awolowo University, Ile-Ife. They were fed on standard rodent pellet (from Vitals Feeds, Plc, Nigeria). The study was performed using thirty-five (35) female albino rats, about eight weeks old (weighing between 140 and 160 g). The animals were allowed three (3) days of acclimatization. Feeds and water were freely available to all animals throughout the period of the experiment. The animals were exposed to natural lighting conditions and handled according to standard protocols. The body weights of the animals were assessed and recorded every week throughout the period of the experiment.

Drug and Equipment

Estradiol benzoate (AK Scientific, USA), goserelin (Astrazeneca; Zoladex[®] 3.6 mg), GOYA[®] olive oil (Irawo Pharmacy, Ile Ife, Nigeria), [Creatinine Assay Kit\(ab65340\)](#), 10% formal saline, 2M NaOH, distilled water; needle and syringes (2 mL), sample tubes, heparinised tubes, dissecting set, dissecting board, Celestron Labs CB2000C Compound Binocular Microscope (Fisher Scientific), animal cages H-18 light, oral feeding cannula steel tube, H18 LIGHT heamatology analyser (SFRI, France), weighing balance (Metler Toledo

PB 150).

Preparation of the herbal recipe

The herbal formulation was prepared following the herbalist approach as follows: “the collected plant vegetative parts were air-dried and powdered. Equal amount (0.6 Kg) of each of the four plant materials were weighed separately and mixed together followed by boiling in 6 Litres of corn-fermented water ('omidun' in local dialect) for 2 hours and allowed to cool”. The decoction was filtered and then concentrated to dryness *in-vacuo* using rotary evaporator. The crude extract was kept in a desiccator until needed.

PHARMACOLOGICAL STUDIES

Acute toxicity test

The LD₅₀ for the crude extract was carried out using the method described by Lorke²³ using a total of thirteen (13) rats in two phases. Phase I involves nine (9) rats divided into three (3) groups of three (3) rats each (n=3), while Phase II used three (3) rats, based on the result of phase I, divided into three (3) groups of n=1. In Phase I, the three groups were administered doses of 10, 100 and 1000 mg/kg of the extract respectively. The animals were then monitored constantly for the first six (6) hours, and then intermittently over a period of 24 hours in order to record mortality. Phase II evaluation was carried out based on the result of the Phase I. This consisted of three (3) groups (n=1) that were administered doses of 1600, 2900 and 5000 mg/kg of the extract respectively. All administrations of the crude extract were by oral gavage route.

Induction of uterine leiomyoma

Uterine leiomyoma was induced in female rats according to the method of Chen *et al.*²⁴ as modified. This involved the intramuscular administration of 200 µg of estradiol benzoate using GOYA[®] Olive oil as vehicle. The administration was done on a 72-hourly basis for eight (8) weeks. The induction of uterine leiomyoma was confirmed by histological examinations.

Treatment of the animals

After *uterine leiomyoma* induction, the animals were divided into seven (7) groups of n=5. Group 1 received placebo (fermented corn water). The treatment doses were determined based on the result of the acute toxicity tests. Groups 2, 3 and 4 received doses of 600, 800 and 1000 mg/kg of the extract respectively, on 48-hourly basis for

two weeks^{25,26}. Group 5 received a dose of 1500 mg/kg bolus dose for a day, then followed by 500 mg/kg dose for three (3) days consecutively. The sixth group was the positive control group which was administered goserelin (0.1mg/kg body weight). Group seven (Control group) contains animals in which uterine leiomyoma was not induced nor were they administered the extract but were kept in the same environment and condition as the other groups. Forty-eight (48) hours after the last dose of treatment, the animals were sacrificed after being anaesthetized with diethyl ether. Cardiac puncture was carried out to collect blood into heparinised tubes. The uterus was excised from the body following abdominopelvic incisions, weighed and collected into 10% v/v formal saline, in sample tubes.

HAEMATOLOGICAL ASSESSMENT OF BIOMARKERS

Haematological analysis was done few minutes after the collection of the blood at Haematology and Immunology Department, College of Health Sciences, Obafemi Awolowo University, Ile Ife with H-18 light autoanalyser, an haematology blood cell counter with three (3) part leukocyte sub-population differentiation. The parameters determined were; white blood cell (WBC), lymphocytes (LYM), monocytes (MON), granulocyte (GRAN), lymphocyte percent (LYMPH%), monocyte percent (MON%), granulocyte (GRAN%), red blood cell (RBC), haemoglobin concentration (HGB), haematocrit (HCT), mean cell volume (MCV), mean cell haemoglobin (MCH), mean cell haemoglobin concentration (MCHC), red blood cell distribution width standard deviation (RDW-SD), red blood cell distribution width coefficient of variation (RDW-CV), platelet (PLT), mean platelet volume (MPV), platelet distribution width (PDW), plateletcrit (PCT), platelet-large cell ratio (P-LCR). The result obtained was then analysed, comparing the test groups with the placebo and control.

BIOCHEMICAL ASSESSMENT OF CREATININE CONCENTRATION

Biochemical analysis was done to determine the level of creatinine in the blood plasma. The blood samples were centrifuged at 250 rpm for thirty (30) minutes, the plasma was separated into non-heparinised tubes and kept in a refrigerator until the tests were carried out. Creatinine concentration was determined using Creatinine Assay Kit (ab65340) following the manufacturer's instructions at the Department of Biochemistry, Obafemi Awolowo University, Ile-Ife. For Creatinine determination, equal volumes of Reagent 1 (Picric acid 35 mmol/L) and Reagent

2 (Sodium hydroxide 0.32 mmol/L) were mixed in a beaker to give the working reagent. A standard Reagent was also pipetted in triplicate into wells of microtitre plates. 25 µL of the blood plasma was then pipetted in triplicate into wells of microtitre plates. 250 µL of the working reagent was added to the plasma and standard reagent in the wells, mixed and left to stand for 30 seconds and the absorbance at 492 nm were measured and recorded as A1. The plates were then allowed to stand for 2 minutes and the absorbance was also measured at the same wavelength and recorded as A2.

$$A2 - A1 = \Delta A_{\text{sample}} \text{ or } \Delta A_{\text{standard}}$$

$$\text{Concentration of creatinine in plasma} = (\Delta A_{\text{sample}} / \Delta A_{\text{standard}}) \times 180 \mu\text{mol/L.}$$

HISTOLOGICAL ANALYSIS

The histopathology of the uterus was carried out at the Department of Anatomy and Cell Biology, College of Health Sciences, Obafemi Awolowo University, Ile-Ife.

The excised uteri were immediately fixed in 10% v/v formal saline, and processed for paraffin wax embedding. Thick sections (5 µ) (cross-sections of the uterus) were cut with the aid of a rotary microtome and stained using Hematoxylin and Eosin stains. Digital photomicrographs of the thickest parts of the walls of the uteri were taken at x100 magnifications.

Statistical analysis

Data were analysed using Graphpad Prism version 5.0 for Windows (Graphpad software, San Diego, California, USA). Data were compared using one-way ANOVA, with student Newman Kuels post hoc test for multiple comparisons. Results were expressed as mean ± standard error of mean and level of significance taken as P<0.05.

Result and discussions

The acute toxicity test showed no death of animal up to 5000 mg/Kg body weight indicating the crude extract was safe to the animals.

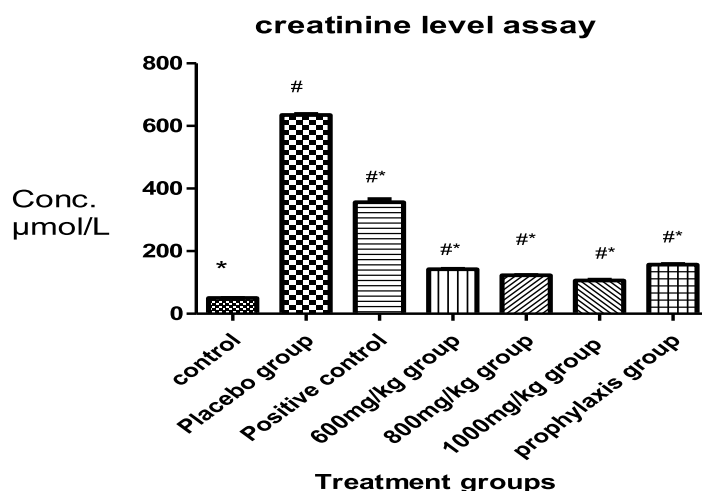
Table 1: Results of acute toxicity testing in rats within 24 hours

Phase	Dose of the extract	Mortality
1	10 mg/kg	0/3
	100 mg/kg	0/3
	1000 mg/kg	0/3
2	1600 mg/kg	0/1
	2900 mg/kg	0/1
	5000 mg/kg	0/1

Table 2: Effects of the administration of CKNS extract on weight of the animals.

Group	Mean weight (g) before treatment	Mean weight (g) after treatment	Mean weight (g) of the uterus
Control	160.00 ± 0.80	170.00 ± 2.05	0.50 ± 0.01
Placebo	155.00 ± 1.05	170.00 ± 0.85	1.70 ± 0.06
Goserelin	140.00 ± 3.06	155.00 ± 2.05	1.20 ± 0.02
600 mg/kg	155.00 ± 1.25	165.00 ± 1.04	0.90 ± 0.01
800 mg/kg	145.00 ± 0.55	155.00 ± 2.25	1.10 ± 0.04
1000 mg/kg	155.00 ± 1.02	165.00 ± 1.50	0.80 ± 0.03
Prophylaxis	143.00 ± 0.98	150.00 ± 2.08	1.30 ± 0.01

Figure 1: Chart showing creatinine levels. Each bar and column represents Mean \pm SEM ($p < 0.05$)



Effect of different treatment regimen on creatinine level in estradiol induced fibroid in female rats. Each column and bar represents MEAN \pm SEM ($P < 0.05$). Control group (fibroid was not induced), Placebo group (induction and given fermented corn water only), Positive control (induction and given 0.1 mg/kg goserelin), Extract groups (induction and given 600, 800 and 1000 mg/kg respectively). *means $P < 0.05$ compared to placebo, # means $P < 0.05$ compared to control.

Parameter	Control	Untreated fibroid	Goserelin (0.1 mg/kg)	600 mg/kg	800 mg/kg	1000 mg/kg	Prophylaxis (500 mg/kg)
WBC $\times 10^3$ /UL	1.50 \pm 0.05	5.60 \pm 0.80 [#]	3.40 \pm 0.57	3.50 \pm 1.76	3.07 \pm 1.03	3.30 \pm 0.80	3.68 \pm 1.42
RBC $\times 10^3$ /UL	5.28 \pm 0.41	6.330 \pm 0.46	5.77 \pm 0.57	5.64 \pm 0.33	5.42 \pm 0.51	6.29 \pm 0.30	6.08 [#] \pm 0.16
LYM $\times 10^3$ /UL	0.90 \pm 0.34	3.93 \pm 1.07	2.30 \pm 0.57	2.78 \pm 1.11	2.28 \pm 1.07	2.00 \pm 0.57	1.77 \pm 0.67
PLT $\times 10^3$ /UL	467.0 \pm 19.7	790.0 \pm 11.5	813.0 \pm 10.7	664.7 \pm 247.6	1042.0 \pm 108.8	1217 \pm 302	383.6 \pm 48.2
HGB (g/dL)	12.0 \pm 0.38 [#]	10.60 \pm 0.65	10.77 \pm 0.75	11.40 \pm 0.561	11.95 \pm 1.10	12.30 \pm 0.50	12.10 \pm 0.456
HCT%	25.50 \pm 1.76	40.60 \pm 3.20	34.00 \pm 3.30	35.67 \pm 3.14	37.30 \pm 4.37	41.70 \pm 1.20	30.02 \pm 1.26
MCV (fL)	48.40 \pm 0.33	64.10 \pm 0.65	65.40 \pm 0.48 [#]	63.10 \pm 3.09	68.67 \pm 4.00	66.40 \pm 1.20	49.38 \pm 0.93
MCH (pg)	22.70 \pm 0.42	19.10 \pm 0.65	20.40 \pm 0.56	19.30 \pm 0.21	20.73 \pm 0.52	19.10 \pm 0.10	17.96 \pm 0.30
MCHC (g/dL)	47.00 \pm 0.57	29.80 \pm 0.65	31.20 \pm 0.70 [#]	30.70 \pm 1.40	29.73 \pm 0.52	28.75 \pm 0.35	36.48 \pm 0.12 [#]
LYM%	59.90 \pm 5.92	90.50 \pm 6.68	66.60 \pm 7.00	64.27 \pm 6.42	77.73 \pm 5.75	60.90 \pm 2.30	73.68 \pm 4.16
MPV (fL)	7.10 \pm 0.27	7.10 \pm 0.40 [#]	7.90 \pm 0.35	7.57 \pm 0.37	7.60 \pm 0.40	7.60 \pm 0.35	6.58 \pm 0.20
RDW-SD (fL)	31.60 \pm 0.55	29.90 \pm 3.25	36.40 \pm 0.310	32.43 \pm 0.43	38.00 \pm 1.45	33.75 \pm 0.65	28.6 \pm 0.74
RDW-CV%	15.90 \pm 1.23	11.00 \pm 1.50	14.00 \pm 1.35	12.77 \pm 0.92	14.67 \pm 2.37	12.35 \pm 0.05	14.16 \pm 0.34
PDW%	7.70 \pm 0.76	8.00 \pm 0.95	9.90 \pm 0.87	9.30 \pm 0.81	8.30 \pm 0.92	9.20 \pm 0.80	8.14 \pm 0.42
PLCR%	0.00 \pm 0.00	7.90 \pm 2.50	9.98 \pm 2.83	5.60 \pm 2.02	3.68 \pm 1.31	3.24 \pm 1.51	3.70 \pm 1.67
PCT%	0.33 \pm 0.02	0.56 \pm 0.04	0.64 \pm 0.04 [#]	0.49 \pm 0.17	0.79 \pm 0.13	0.81 \pm 0.18	0.25 \pm 0.03

Control group (fibroid was not induced), Placebo group (induction and given fermented corn water only), Positive control (induction and given 0.1 mg/kg goserelin), Extract groups (induction and given 600, 800 and 1000 mg/kg respectively). # represents a significant ($p < 0.05$) difference in the specified haematological parameter when compared to control group; *represents a significant ($p < 0.05$) difference when compared to the placebo group.

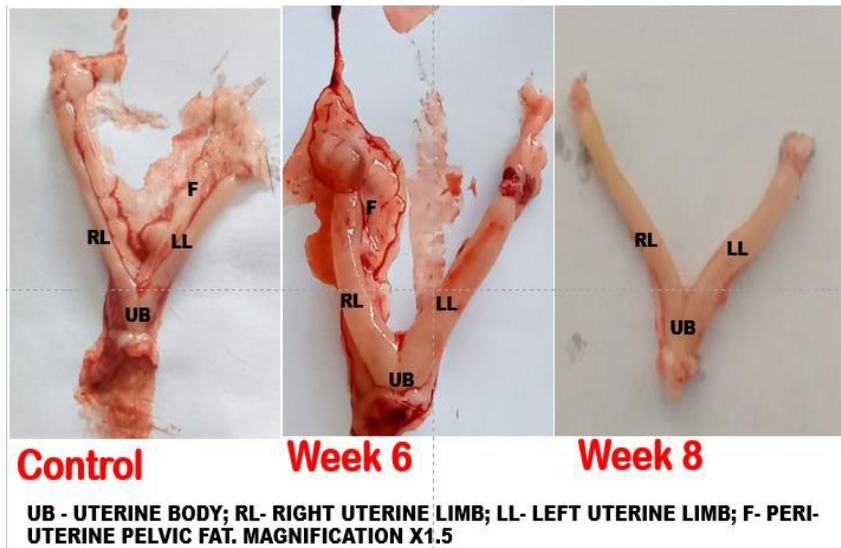


Figure 2: Gross anatomy of the uterus in the control and fibroid induced female rats.

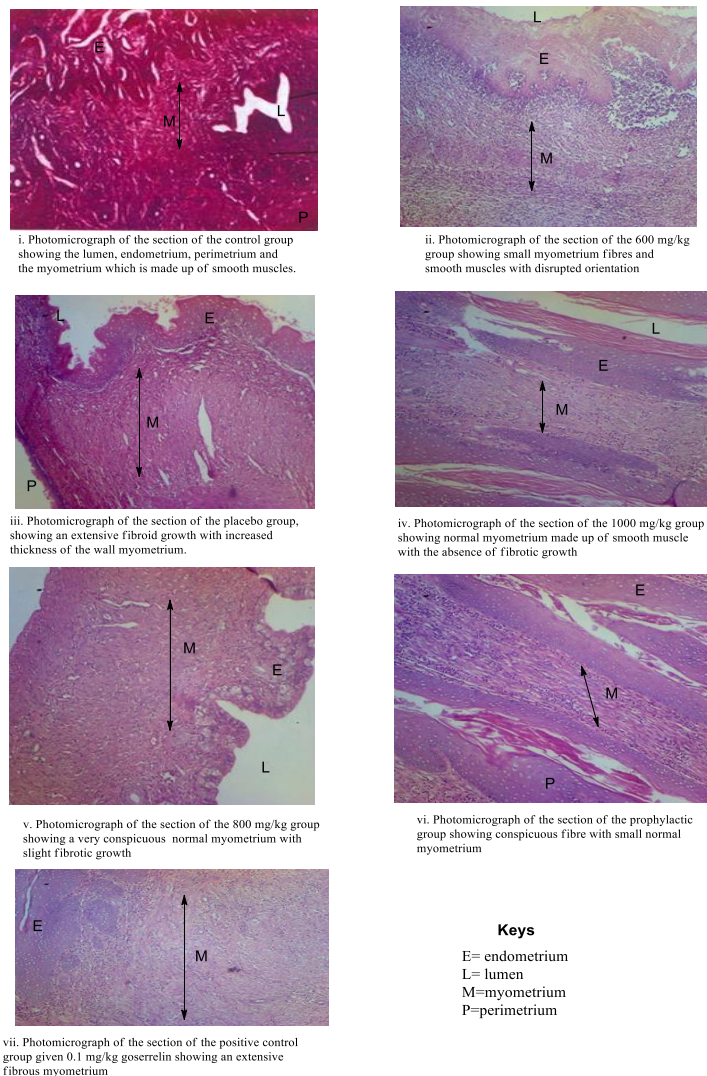


Figure 3: H&E stained histologic cross sections of the uterine wall in all groups showing the histologic layers of the uterus, especially the thickness of the myometrium. Mag. X100

Discussion

Fibroid is a public health challenge with only 25% of women who have symptomatic fibroid experiencing heavy or prolonged menstrual bleeding that often leads to severe iron-deficiency anemia, pelvic pain, extrinsic compression of bowel or bladder, false appearance of pregnancy, and reproductive impairment, that include infertility and pregnancy complications²⁷. Fibroid disease is still held like menstrual period in women, with only few people talking about it, except when it becomes seriously symptomatic. Even then, most women are rarely comfortable with myomectomy, the surgical removal of the fibroid mass from the uterus, due to fear and their cultural inclinations. This makes patronage of herbalists commonplace in South West Nigeria. Also, among the tradomedical practitioners, the most prosperous ones are those handling gynaecological cases, of which fibroid rates very high. However, there are very few scientific investigation if any at all, to validate the herbs used in the local management of fibroid diseases. This study carried out an evaluation of the safety and efficacy of one recipe, generously volunteered by an experienced herbalist who have been involved in managing uterine fibroid disease in Ibarapa Local Government of Oyo State, South West Nigeria. The extract had been administered to women with symptomatic uterine fibroid ethnomedicinally with high satisfaction rate and no complaint(s) of adverse effects (Personal communication).

The four plants that made up the recipe were each collected, dried, powdered and weighed separately. Equal amount of each of the plants powdered vegetative parts was weighed, mixed together and extracted with fermented corn water, following the herbalist instruction. The crude extract obtained was coded *CKNS*. Scientifically, the toxicity profile of the concentrated extract in rats was evaluated using the Lorke's method²³. In the assay, the absence of mortality in rats in all the dose groups throughout the 48 hours of the acute toxicity experiment, showed that the LD₅₀ of the *CKNS* extract was greater than 5000 mg/kg. Hence, *CKNS* extract (subsequently referred to as extract) can be regarded as safe for oral administration. For bioassay, there was a need to adapt a model of uterine fibroid in laboratory animals. Uterine fibroid has been agreed to be a hormonal disease, involving estrogen and progesterone⁵. A study had previously shown that estradiol was a candidate drug for the development of model for experimental induction of uterine fibroid in rats.²⁴ Although several dosing paradigms for such induction have been reported, administration of a dose of 200 µg of estradiol benzoate for eight weeks was employed in this study, informed by the acute toxicity test

results. The histology results indicated the formation of the fibroid mass consequent upon the administration of estradiol benzoate (Figure 2) while the photomicrographs of the cross-sections through the uteri of the various animal groups showed different degree of extensive fibrous nature of the uterus (Figure 3).

One of the major adverse effect of uterine fibroid is heavy menstrual bleeding¹⁷ leading to severe iron deficiency anaemia²⁷. Therefore decreased haemoglobin levels have been reported in patients with *uterine leiomyoma*.¹⁷ This study therefore examined the haematological profile of the extract in the rats groups (Table 3). The placebo group had the lowest haemoglobin level (10.60 ± 0.65 g/dL), while the 1000 mg/kg and the prophylactic treatment groups had haemoglobin levels comparable with the control group. The haemoglobin levels of the two groups all fell within the rat haematologic reference range of 12.10–14.70 g/dL for female Wistar rats²⁸ and was also in agreement with the previous range of 11.5–16.1 g/dL^{29,30}. This indicated that the extract was capable of reversing decreased haemoglobin levels in the rats.

Uterine fibroids often leads to renal impairment^{31,32} characterized by increased creatinine and urea levels³³. Creatinine, is a metabolic product of creatinine phosphate, which is majorly excreted through the kidney. The serum creatinine level has been reported to indicate the rate of glomerular filtration^{34,35}. Thus an elevation in the concentration of serum creatinine level is an indication of a compromised renal function. In this experiment, out of all the animal groups, the control group had the lowest serum creatinine level of 50 µmol/L, indicating good renal function. However the placebo group had an extremely high serum creatinine level of 635.3 µmol/L (Figure 1) while the treatment groups had a value approximately twice or thrice the value of control group. This indicates that the induction of fibroid actually raised the creatinine level while the administration of the herbal formulation was able to lower the level. This confirmed that the extract had positively impacted the renal function of the rats used in the study.

Literature have shown that uterine fibroid patients do have an increase in body weight³⁴. Thus the measurement of the body weight was carried out to determine the health status of the study animals during the duration of treatment. There was a significant difference in the body weights of rats between the start of the treatment and the end, in all the groups (p<0.05). It was noticed that the placebo group had the highest weight difference of 0.015 kg, at the end of the

study, compared to other treatment groups. This result is therefore in agreement with the clinical reports³⁴.

As expected, the control group showed no development of fibroid upon histological examination as the lumen, endometrium, myometrium and perimetrium were clearly defined. The placebo group had an extensive fibroid growth that almost completely blocked the uterine lumen with increased thickness of the middle layer of the wall of the uterus and there was no presence of normal myometrium which indicated that uterine leiomyoma was successfully induced. Histological evaluation of the group that received 600 mg/kg dose of the *CKNS* extract showed the presence of reduced myometrium fibres of smooth muscles with disrupted orientation, from the cross sectional sections of the uterus taken during grossing and microtomy, compared with the placebo group that showed very thick presence of fibrous tissues. On the other hand, the group that received 800 mg/kg of *CKNS* extract had a normal myometrium made up of smooth muscles but with slight fibrotic growth. Similarly, the group that received 1000 mg/kg of *CKNS* extract showed no development of fibroid because the myometrium was made up of smooth muscles with the absence of fibrosis. On the whole, there was a reduction in the extent of the fibres observed in the myometrium, as the dose of the administered extract increased. Therefore, the result showed that *CKNS* extract possessed the ability to reverse the fibrosis of the uterus in a dose dependent manner. The drug used as positive control, goserelin, a gonadotropin releasing hormone agonist was being used in clinical settings for contraception. However, it was being used in fibroid disease to reduce the heavy menstrual bleeding and possibly shrink the fibroid tissue prior to surgical operation³⁷. In this study, the extract outperformed the drug at the dose of 600 and 1000 mg/kg body weight, reducing the average weight of the uterus to 0.9 g and 0.76 g (Table 2) respectively, against 1.2 g for goserelin.

A review of the phytochemistry of each of the four plants contained in the recipe supported its use for antitumour activity in uterine fibroid management. For instance, lapachol isolated from the root, stem bark and fruit of *Kigelia africana* had been previously reported to be effective against melanoma cell lines using 3-(4,5-dimethyl)thiazol-2-yl-2,5-diphenyl tetrazolium bromide (MTT) and Sulforhodamine B (SRB) colourimetric assay for cytotoxicity screening³⁸. Also, norvibutinal and isopinnatal isolated from the ethanolic fruit extract of *Kigelia africana* exhibited cytotoxic activity³⁹ while

kigellinone (5 or 8-hydroxy-2-(1-hydroxyethyl)naphtha(2,3-b)furan-4,9-dione isolated from the stem bark extract had antitumor activity⁴⁰. The leaves of *Spondias mombin* contains essential oils e.g. beta-caryophyllene and gamma-cadinene, which have been tested for cytotoxicity using brine shrimp assay and the oils have shown great activity⁴¹. Also, mombinrin (a coumarin), mombincone, mombinoate and mombionol which are very cytotoxic to mycobacterial cells have been isolated from the leaves⁴². *Newbouldia laevis* belongs to the same family as *K. africana*, i.e Bignoniaceae and it contains lapachol. 2,3,19-trihydroxy-12-ursen-28-oic acid; 3,19-dihydroxy-12-ursen-28-oic acid; 3-hydroxy-12-ursen-28-oic acid and 3-hydroxy-12-oleanen-28-oic acid isolated from the plant exhibited significant cytotoxicity *in vitro* against ST-57 brain tumor transformed fibroblasts⁴³. 2-acetylfuro-1,4-naphthoquinone also reported in *N. laevis* has been reported to be cytotoxic. Hela cells and melanomacolo-38 cells were very sensitive to the leaf extract⁴⁴. *Citrullus colocynthis* (Cucurbitaceae) contains cucurbitacins which have been shown to have antitumor activities against breast CMCF-73, lung NA-H460, colon HCT-116 and brain SF-268 cancer cells⁴⁵. Cucumol, a triterpenoid isolated from the fruit was found to possess antitumor activity against mouse lymphoma (C5L178Y) and human cervix HeLa cancer cells⁴⁶. These activities justify why the recipe has antitumour activity and validate its use in the management of uterine fibroid diseases.

CONCLUSION

The result obtained for both acute toxicity testing, haematological study, biochemical analysis, weight variation and the histological study indicated that the *CKNS* extract is safe for oral administration in rats. The study demonstrated effectiveness in restoring the haemoglobin level in a fibrotic rat, and it enhanced the renal function. *CKNS* led to better shrinkage of fibroid than goserelin while it reversed fibrosis in rats. This study therefore validated the use of the recipe in management of uterine fibroid diseases.

Acknowledgement: The generous volunteering of the recipe by Mr Olojede 'Biya is gratefully acknowledged

Funding: TETFUND NRF grant 2021 TETFES/DR&D/CE/NRF-2021/SETI/HSW/000509/VOL.1/

References

1. Ogedengbe OK (2003) Uterine Fibroids In: Contemporary obstetrics and gynaecology for developing countries. Okonofua, F. and Odunsi, K. (Ed) Intec printers limited Ibadan. Pg 202 – 213.
2. Islam MS, Protic O, Stortoni P, Grechi G, Lamanna P, Petraglia F, Castellucci M, Ciarmela P (2013) Complex networks of multiple factors in the pathogenesis of uterine leiomyoma. *Fertility and Sterility* 100(1):178-193. doi: 10.1016/j.fertnstert.2013.03.007.
3. Williams ARW (2017). Uterine fibroids - what's new? *F1000Research*. 6:2109. doi: 10.12688/f1000research.12172.1.
4. Taylor DK, Holthouser K, Segars JH, Leppert PC (2015) Recent scientific advances in leiomyoma (uterine fibroids) research facilitates better understanding and management. *F1000Res*. 4(F1000 Faculty Rev):183. doi: 10.12688/f1000research.6189.1.
5. Cramer SF, Patel A (1990) The frequency of uterine leiomyomas. *94(4):435-438*. doi: 10.1093/ajcp/94.4.435.
6. Marshall LM, Spiegelman D, Barbieri RL, Goldman MB, Manson JE, Colditz GA, Willett WC, Hunter DJ (1997) Variation in the incidence of uterine leiomyoma among premenopausal women by age and race. *Obstetrics and Gynecology*. 90(6):967-973. doi: 10.1016/s0029-7844(97)00534-6.
7. Baird DD, Dunson DB, Hill MC, Cousins D, Schectman JM (2003) High cumulative incidence of uterine leiomyoma in black and white women: ultrasound evidence. *American Journal of Obstetrics and Gynecology*. 188(1):100-107. doi: 10.1067/mob.2003.99.
8. Eltoukhi HM, Modi MN, Weston M, Armstrong AY, Stewart EA (2014) The health disparities of uterine fibroid tumors for African American women: a public health issue. *American Journal of Obstetrics and Gynecology*. 210(3):194-199. doi: 10.1016/j.ajog.2013.08.008. Epub 2013 Aug 11.
9. Sengoba KS, Ghant MS, Okeigwe I, Mendoza G, Marsh EE (2017) Racial/Ethnic Differences in Women's Experiences with Symptomatic Uterine Fibroids: a Qualitative Assessment. *Journal of Racial and Ethnic Health Disparities*. 4(2):178-183. doi: 10.1007/s40615-016-0216-1. Epub 2016 Apr 11. PMID: 27068661; PMCID: PMC5064808.
10. Ogunniyi S.O., Fasuba O. (1990) Uterine fibromata in Ilesha, Nigeria. *Nigerian Medical Practitioner* 191:93-95.
11. Obuna JA, Umeora OU, Ejikeme BN, Egwuatu VE (2008) Uterine fibroids in a tertiary health centre South East Nigeria. *Nigerian Journal of Medicine*. 17(4):447-451.
12. Akinyemi BO, Adewoye BR, Fakoya TA (2004) Uterine fibroids. A review. *Nigerian Journal of Medicine* 13(4):318-329.
13. Isah AD, Adewole N, Agida ET and Omonua KI (2018) A Five-Year Survey of Uterine Fibroids at a Nigerian Tertiary Hospital. *Open Journal of Obstetrics and Gynecology*, 8, 468-476. <https://doi.org/10.4236/ojog.2018.85053>
14. Aboyeji AP and Ijaiya MA (2002) Uterine fibroids. A ten year clinical review at University of Ilorin Teaching Hospital, Ilorin, *Nigerian Journal of Medicine*. 11(1): 16–19.
15. Zimmermann A, Bernuit D, Gerlinger C, Schaeffers M, Geppert K (2012) Prevalence, symptoms and management of uterine fibroids: an international internet-based survey of 21,746 women. *BMC Womens Health* 12:6
16. Borah BJ, Nicholson WK, Bradley L, Stewart EA (2013) The impact of uterine leiomyomas: a national survey of affected women. *American Journal of Obstetrics and Gynecology*. 209(4):319.e1-319.e20. doi: 10.1016/j.ajog.2013.07.017.
17. Nelson AL, Ritchie JJ (2015) Severe anemia from heavy menstrual bleeding requires heightened attention. *American Journal of Obstetrics and Gynecology*. 213(1):97.e1-97.e6. doi: 10.1016/j.ajog.2015.04.023..
18. Friedman AJ, Lobel SM, Rein MS, Barbieri RL (1990) Efficacy and safety considerations in women with uterine leiomyomas treated with gonadotropin-releasing hormone agonists: the estrogen threshold hypothesis. *American Journal of Obstetrics and Gynecology*. 163(4 Pt 1):1114-9. doi: 10.1016/0002-9378(90)90667-v.
19. Adamson GD (1992) Treatment of uterine fibroids: current findings with gonadotropin-releasing hormone agonists. *American Journal of Obstetrics and Gynecology*. 1992

- Feb;166(2):746-51. doi: 10.1016/0002-9378(92)91707-h.
20. Mahase E (2020) Uterine fibroid drug is recalled after case of liver failure requiring transplant prompts EU review. *BMJ*. 368:m1112. doi: 10.1136/bmj.m1112.
 21. Al-Hendy A, Myers ER, Stewart E (2017) Uterine Fibroids: Burden and Unmet Medical Need. *Seminars in Reproductive Medicine*. 35(6):473-480. doi: 10.1055/s-0037-1607264. Epub 2017 Nov 3.
 22. Ciebiera M, Łukaszuk K, Męczekalski B, Ciebiera M, Wojtyła C, Stabuszewska-Jóźwiak A, Jakiel G (2017) Alternative Oral Agents in Prophylaxis and Therapy of Uterine Fibroids-An Up-to-Date Review. *International Journal of Molecular Sciences* 18(12):2586. doi: 10.3390/ijms18122586.
 23. Lorke D (1983) A new approach to practical acute toxicity testing. *Archives of Toxicology*. 54(4):275-87. doi: 10.1007/BF01234480.
 24. Chen HG, Lan Z, Cui QC, Lang JH, Li B (2011) [Estrogen induced rat model of uterine leiomyoma]. *Zhongguo Yi Xue Ke Xue Yuan Xue Bao*. 33(4):408-11. Chinese. doi: 10.3881/j.issn.1000-503X.2011.04.012.
 25. Wagner JG (1978) Time to reach steady state and prediction of steady-state concentrations for drugs obeying Michaelis-Menten elimination kinetics. *Journal of Pharmacokinetics and Biopharmaceutics* 6(3):209-225. doi: 10.1007/BF01312263.
 26. Richens A (1975) A study of the pharmacokinetics of phenytoin (diphenylhydantoin) in epileptic patients, and the development of a nomogram for making dose increments. *Epilepsia*. 16(4):627-646. doi: 10.1111/j.1528-1157.1975.tb04745.x.
 27. Stewart EA, Nowak RA (2022) Uterine Fibroids: Hiding in Plain Sight. *Physiology* (Bethesda). 37(1):16-27. doi: 10.1152/physiol.00013.2021.
 28. Patel S, Patel S, Kotadiya A, Patel S, Shrimali B, Joshi N, Patel T, Trivedi H, Patel J, Joharapurkar A, Jain M (2024) Age-related changes in hematological and biochemical profiles of Wistar rats. *Laboratory Animal Research*. 40(1):7. doi: 10.1186/s42826-024-00194-7.
 29. Delwatta SL, Gunatilake M, Baumans V, Seneviratne MD, Dissanayaka MLB, Batagoda SS, Udagedara AH, Walpola PB (2018) Reference values for selected hematological, biochemical and physiological parameters of Sprague-Dawley rats at the Animal House, Faculty of Medicine, University of Colombo, Sri Lanka. *Animal Models and Experimental Medicine*. 21;1(4):250-254. doi: 10.1002/ame2.12041.
 30. Jacob Filho W, Lima CC, Paunksnis MRR, Silva AA, Perilhão MS, Caldeira M, Bocalini D, de Souza RR (2018) Reference database of hematological parameters for growing and aging rats. *Aging Male*. 21(2):145-148. doi: 10.1080/13685538.2017.1350156.
 31. Okogbo FO, Ezechi OC, Loto OM, Ezeobi PM (2011) Uterine Leiomyomata in South Western Nigeria: a clinical study of presentations and management outcome. *African Health Sciences*. 11(2):271-278.
 32. Al Hadidi S, Shaik Mohammed T, Bachuwa G (2015). Unusual presentation of uterine leiomyoma. *BMJ Case Report*. 2015:bcr2014208995. doi: 10.1136/bcr-2014-208995.
 33. Fletcher HM, Wharfe G, Williams NP, Gordon-Strachan G, Johnson P (2013). Renal impairment as a complication of uterine fibroids: a retrospective hospital-based study. *Journal of Obstetrics and Gynaecology*. 33(4):394-398. doi: 10.3109/01443615.2012.753421.
 34. Gregory L, Birgel Junior EH, D'angelino FJ (2004). Valores de referenciados teores séricos da uréia e creatinina em bovinos da raça Jersey criados no Estado de São Paulo. Influência dos fatores etários, sexuais e da infecção pelo vírus da leucose dos bovinos. *Arquivos do Instituto Biológico*. 71:39-345.48.
 35. Marshall W. (2012) Urea (serum, plasma). Association for Clinical Bio-chemistry. Tooley street, London 1-5
 36. Ojo OC and Ajibade OO (2013) "Evaluation of Marker Enzymes in Fibroid Patients." *IOSR Journal of Environmental Science, Toxicology and Food Technology* 5 (2013): 29-31.
 37. West CP, Lumsden MA, Lawson S, Williamson J, Baird DT (1987) Shrinkage of uterine fibroids during therapy with goserelin (Zoladex): a luteinizing hormone-releasing hormone agonist administered as a monthly subcutaneous depot. *Fertility and Sterility*. 48(1):45-51. doi: 10.1016/s0015-0282(16)59288-7.

38. Higgins CA, Bell T, Delbederi Z, Feutren-Burton S, McClean B, O'Dowd C, Watters W, Armstrong P, Waugh D, van den Berg H. (2010) Growth inhibitory activity of extracted material and isolated compounds from the fruits of *Kigelia pinnata*. *Planta Medica* 76(16):1840-6. doi: 10.1055/s-0030-1250046.
39. Jackson SJ, Houghton PJ, Retsas S, Photiou A (2000). *In vitro* cytotoxicity of norviburtinal and isopinnatal from *Kigelia pinnata* against cancer cell lines. *Planta Medica*. 66(8):758-61. doi: 10.1055/s-2000-9778.
40. Graham JG, Quinn ML, Fabricant DS, Farnsworth NR (2000) Plants used against cancer - an extension of the work of Jonathan Hartwell. *Journal of Ethnopharmacology*. 73(3):347-77. doi: 10.1016/s0378-8741(00)00341-x.
41. Oladimeji AO, Aliyu MB, Ogundajo AL, Babatunde O, Adeniran OI, Balogun OS (2016) Identification and comparison of the volatile constituents of fresh and dried leaves of *Spondias mombin* found in North-central Nigeria: *in vitro* evaluation of their cytotoxic and antioxidant activities. *Pharmaceutical Biology*. 54(11):2674-2678. doi: 10.1080/13880209.2016.1178308.
42. Olugbuyiro JAO and Moody JO (2013). Antitubercular compounds from *Spondia mombin*. *International Journal of Pure and Applied Science and Technology*. 19(2): 76-87
43. Onocha PA, Okorie DA, Krebs HC, Meier B (2011) *In vitro* Cytotoxic Pentacyclic Triterpenoids of *Newbouldia laevis*. *Research Journal of Medical Sciences* 5:330-335.
44. Kuete V, Wabo HK, Eyong KO, Feussi MT, Wiench B, Krusche B, Tane P, Folefoc GN, Efferth T (2011). Anticancer activities of six selected natural compounds of some Cameroonian medicinal plants. *PLoS One*. 6(8):e21762. doi: 10.1371/journal.pone.0021762.
45. Hussain AI, Rathore HA, Sattar MZ, Chatha SA, Sarker SD, Gilani AH (2014) *Citrullus colocynthis* (L.) Schrad (bitter apple fruit): a review of its phytochemistry, pharmacology, traditional uses and nutritional potential. *Journal of Ethnopharmacology*. 155(1):54-66. doi: 10.1016/j.jep.2014.06.011.
46. Ibrahim S., Al Haidari R., Mohamed G., Elkhayat E., Moustafa M. (2016) Cucumol A: a cytotoxic triterpenoid from *Cucumis melo* seeds. *Revista Brasileira de Farmacognosia* 26(6). <https://doi.org/10.1016/j.bjp.2016.03.012>